

# Retropharyngeal abscess in a 56-year old man – a rare complication of odontogenic inflammatory state. Author's own proposal for effective drainage

## Ropień zagardłowy u 56-letniego mężczyzny – rzadkie powikłanie zębopochodnego stanu zapalnego. Własna propozycja skutecznego drenażu

Maciej Sikora<sup>1,2</sup>, Marcin Sielski<sup>1</sup>, Agata Stąpor<sup>1</sup>, Dariusz Chlubek<sup>2</sup>✉

<sup>1</sup> Samodzielny Publiczny Zakład Opieki Zdrowotnej Ministerstwa Spraw Wewnętrznych i Administracji, Pododdział Chirurgii Szczękowo-Twarzowej, ul. Wojska Polskiego 51, 25-375 Kielce

<sup>2</sup> Pomorski Uniwersytet Medyczny w Szczecinie, Katedra Biochemii i Chemii Medycznej, al. Powstańców Wlkp. 72, 70-111 Szczecin

✉ dclubek@pum.edu.pl

### ABSTRACT

Retropharyngeal abscess in adults occurs rarely. In a small number of patients it arises as a complication of odontogenic inflammation, as in the case we describe. The key task in the treatment of patients with retropharyngeal abscess is to make the correct diagnosis.

The image examination of choice in adult patients with suspected retropharyngeal abscess should be computed tomography with contrast. After making the correct diagnosis it is necessary to initiate the appropriate treatment (conservative

or surgical). In cases treated surgically the effective and free approach to retropharyngeal space is transcervical access. The effective drainage of the retropharyngeal space using the rinsing drain devised by the authors enabled the total evacuation of residual suppurative content and prevented dangerous complications, such as descending necrotic mediastinitis, leading to the recovery of the patient.

**Keywords:** computed tomography with contrast; drainage of retropharyngeal space; retropharyngeal abscess; rinsing drain.

### ABSTRAKT

Ropień zagardłowy u osób dorosłych jest schorzeniem występującym rzadko. W niewielkiej liczbie przypadków jest to powikłanie zębopochodnego stanu zapalnego implikowanego przyjmowaniem metotreksatu. Przypadek taki został opisany w niniejszej pracy.

W rozpoznaniu ropnia zagardłowego istotną rolę odgrywa diagnostyka obrazowa ze wskazaniem na tomografię komputerową szyi z kontrastem. Po właściwym ustaleniu rozpoznania niezbędne jest szybkie wdrożenie właściwego postępowania terapeutycznego: zachowawczego w postaci antybiotykoterapii

o szerokim spektrum, a w uzasadnionych sytuacjach również chirurgicznego. U chorych leczonych chirurgicznie stosuje się przeszczepny dostęp do przestrzeni zagardłowej. W przypadku opisanym w niniejszej pracy zastosowano drenaż przestrzeni zagardłowej za pomocą drenu płuczącego własnej konstrukcji, który umożliwił skuteczne odprowadzenie treści ropnej. Postępowanie to pozwoliło na uniknięcie niebezpiecznego powikłania, jakim jest zstępujące martwicze zapalenie śródpiersia, i umożliwiło całkowite wyleczenie chorego.

**Słowa kluczowe:** dren płuczący; drenaż przestrzeni zagardłowej; ropień zagardłowy; tomografia komputerowa z kontrastem.

## INTRODUCTION

The retropharyngeal space is a narrow, slit-like anatomical space, which is located between the fascia of the rear wall of the pharynx, and the prevertebral lamina of the cervical fascia of the neck covering the cervical spine and prevertebral muscles [1, 2, 3]. The upper part of it reaches the base of the skull, and the lower part turns into the upper mediastinum. In this space a retropharyngeal abscess may form, which is an example of infections of deep neck spaces (deep neck infections). This ailment occurs almost exclusively in children, of whom the vast majority are under 5 years of age [4, 5]. This is due to the fact that at the age of about 4–5 years the retropharyngeal space is filled with lymph nodes (Henle nodes) [1, 3, 6, 7]. After this

time, according to Cmejrek et al., retropharyngeal lymph nodes undergo spontaneous regression [8]. Retropharyngeal lymph nodes collect lymph from the nasal cavity, pharynx, maxillary sinuses and pharyngeal tonsil [9, 10]. In the course of frequent acute inflammatory ailments of the upper respiratory tract in children lymph nodes situated in the retropharyngeal space may be subject to inflammation [7, 9]. In some cases the inflammation of retropharyngeal lymph nodes can be of a suppurative nature [7, 9, 10]. In the case of the suppuration of Henle lymph nodes retropharyngeal abscess occurs [7, 9, 10, 11]. Starting at the age of about 5, retropharyngeal lymph nodes undergo spontaneous atrophy and, as a consequence, the retropharyngeal space in adults is filled only with flaccid connective tissue [12]. For this reason the occurrence of retropharyngeal abscess in

adults is extremely rare and mostly appears as a complication of: iatrogenic trauma (gastroscopy, intubation, intragastric tube placement) causing suppuration of retropharyngeal haematoma [13, 14], the presence of a foreign body in the rear wall of the pharynx (fish bone, animal bone) [15, 16], osteoarticular tuberculosis of the cervical spine (Pott's disease) [17, 18], or suppurative inflammations of dental origin [19, 20].

Diseases associated with immunity disorders foster the occurrence of retropharyngeal abscess in adults (patients with diabetes and leukaemia, or infected by the HIV virus), as well as clinical conditions, in which immunity is intentionally suppressed and maintained pharmacologically for the purpose of treating the basic ailment (biological treatment of rheumatoid arthritis, treatment with cytostatic drugs in psoriatic arthritis) [21, 22, 23]. Individual cases of retropharyngeal abscess occurrence in patients with nasopharyngeal cancer are also described [24].

## CASE REPORT

A 56-year-old man was treated in the Department of Maxillofacial Surgery, in the Hospital of the Ministry of the Interior in Kielce (Poland). Before being admitted to the department the patient was treated in the Department of Rheumatology at a Hospital in Starachowice. From the data of the hospital discharge summary report of the patient's stay in the department of rheumatology we learned that in connection with a continuously increased level of the erythrocyte sedimentation rate (ESR) and C-reactive protein (CRP), as well as acute symptoms of the knee joint arthritis, methotrexate in a dose of 15 mg/week was administered in the treatment. During his stay in the department of rheumatology an increasing inflammatory infiltration in the area of the pharynx appeared, and during laboratory studies an increase of inflammatory markers and erythrocyturia were observed. In that department the dentist removed a tooth 47, antibiotic therapy (Clindamycin) was initiated, and methotrexate was discontinued. Despite the initiated treatment, progression of inflammatory infiltration on the pharynx and dysphagia were observed. Because of the deterioration of the general condition the patient was moved urgently to the Department of Maxillofacial Surgery, Hospital of the Ministry of the Interior in Kielce (Poland). After being

admitted, the patient complained about difficulties with swallowing, pain and oedema of the cervix, as well as continuing subfebrile body temperature. In the clinical examination in question excessive tension, redness and warmth of neck skin were observed. Trismus of the III degree (opening of jaws for approximately 5 mm) was found. On the day of the patient's admission to the department basic laboratory tests were performed: complete blood count (CBC), electrolyte panel, coagulation panel, as well as urea, creatinine, glucose, and CRP levels in blood plasma. The results of the tests showed a significant increase of CRP level (362.7 mg/L) and a low haemoglobin count (8.6 g/dL). On the same day, a broad spectrum antibiotic therapy (Augmentin 3 × 1.2 iv and Metronidazole 3 × 0.5 iv) and NSAID were introduced. The chest X-ray examination revealed no deviations from standard. In the ultrasonography (USG) examination of the cervix areas with increased echogenicity and numerous enlarged lymph nodes on the cervix, and also fluid pockets in the lower parts of the cervix were found. On the pantomographic X-ray chronic inflammatory periapical lesions in numerous teeth of the maxilla and mandible were found. As a matter of urgency, computed tomography (CT) was performed, in which a retropharyngeal abscess was shown with dimensions of about 8.1 × 3.1 × 6.4 cm. It filled the pre-spinal space, displacing the pharynx forward and the larynx to a lesser extent (Fig. 1). Below the level of the larynx the abscess extended on the sides through the two fluid areas, which dislocated and distorted the thyroid lobes (Fig. 2). The abscess did not penetrate into the chest. The diagnosis of retropharyngeal abscess was made on the basis of the clinical image of the patient and after the analysis of additional tests. Afterwards, because of the deterioration of the patient's general condition and in particular due to the fact that rest dyspnoea occurred during the second day of his stay in the department, the decision about urgent surgical treatment with extraoral access was taken. With access on both sides of the cervix a cut along the front edge of the sternocleidomastoid muscle was made. After cutting the tissues the carotid sheath was identified and reached. After putting it to the side from the right and the left, the retropharyngeal space was accessed. After opening the wall of the abscess, about 80 mL of dense suppurative content was purged from its lumen, and collected for bacteriological tests, including a test for the presence of Koch mycobacteria. Numerous septa were

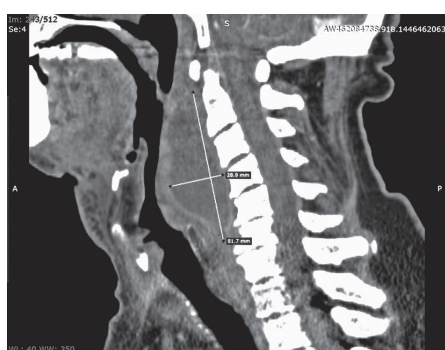

FIGURE 1. Sagittal computed tomography view of the neck before surgery

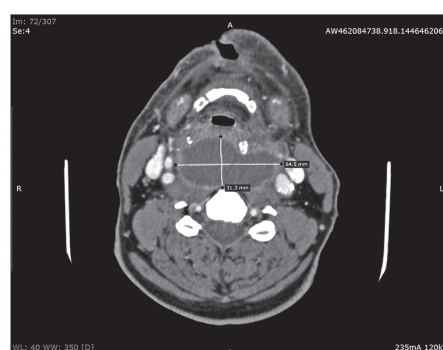
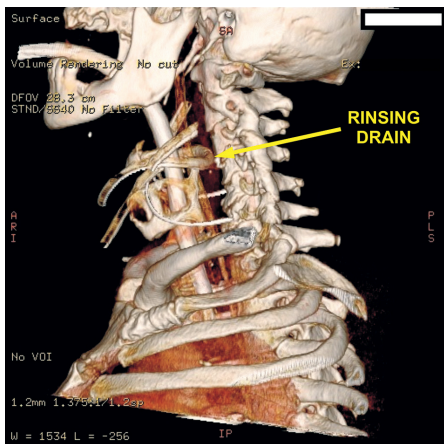
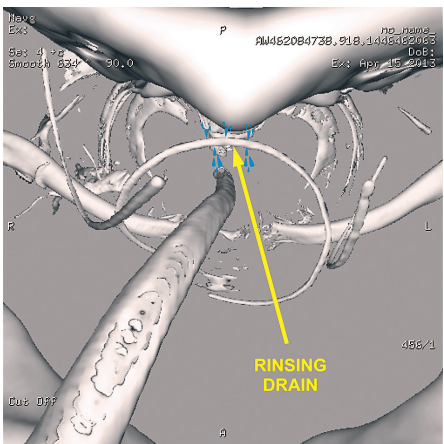


FIGURE 2. Horizontal computed tomography view of the neck before surgery



**FIGURE 3.** Lateral computed tomography view of the neck with rinsing drain (3D reconstruction)

eliminated bluntly, which were in the cavity of the abscess joining the left side with the right. The cavity of the abscess was rinsed repeatedly using normal saline. In view of the extent and multi-compartment nature of the abscess, and the dense suppurative content found in the cavity of the abscess there was concern about the difficult draining of suppurative content from the retropharyngeal space. The retention of suppurative content, in particular in the lower compartments of the abscess, threatened the displacement of suppurative content to the mediastinum and the occurrence of descending necrotic mediastinitis. In view of the above, besides the typical drainage used with single drains left in the cavity of the abscess on both sides, additional drainage was used by means of one drain passed through one side of the neck through the retropharyngeal space and coming out on the other side of the cervix (Fig. 3). This drain was called the rinsing drain. The central part of the rinsing drain, which passed through the retropharyngeal space over a distance of about 5 cm, was perforated – it had a few openings with a diameter of about 3 mm in various places of the perimeter of the drain (Fig. 4). This solution also allowed for rinsing the cavity of the abscess with normal saline (Fig. 5). On the other hand, it enabled the out-flow of suppurative content from the retropharyngeal space.

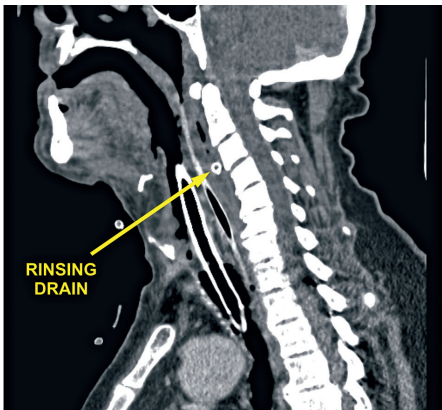


**FIGURE 4.** Volumetric computed tomography reconstruction with graphical visualization of rinsing drain

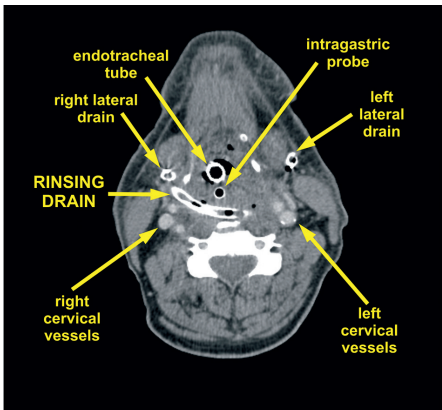
All three drains were sewn to the edges of the skin of the neck in order to prevent their protrusion. At the same time, during the procedure, an absolute sanitation of oral cavity was made. Because of the severe general condition of the patient a prolonged intubation was used, and the patient was fed through the stomach tube. Every day, three times a day, the cavity of the abscess was rinsed using all 3 drains. On the second day after the surgery, due to secondary anaemia (Hb – 7.9 g/dL), two units of packed red blood cells were transfused to the patient. On the following days after surgery an improvement in the clinical status, and regression of biochemical inflammatory markers in the blood were observed. Before removing the drains, and in particular the “rinsing drain”, CT of the cervix was performed, and after confirming the regression of the abscess the decision to remove them was made (Fig. 6 and 7). On the 7<sup>th</sup> day after surgery the patient was extubated due to substantial improvement of his general condition. The patient was discharged from the department on the 4<sup>th</sup> day after the removal of the drain. On the day the patient was discharged from hospital and a week after the end of hospitalization a follow-up USG examination was performed to assess the effectiveness of treatment. In these tests no pathological fluid-filled spaces in the cervix were shown.



**FIGURE 5.** Principle of operation of rinsing drain



**FIGURE 6.** Sagittal computed tomography view of the neck with abscess regression



**FIGURE 7.** Horizontal computed tomography view of the neck with abscess regression



## DISCUSSION AND LITERATURE REVIEW

Retropharyngeal abscess is an ailment which should be treated intensively due to the possibility of complications, some of which can be life-threatening [5, 16, 17, 25]. Herzon and Martin mention the following potential complications: obstruction of the respiratory tract, thrombotic inflammation of the internal jugular vein, thrombotic inflammation of the cavernous sinus, erosion of the carotid artery wall (possible massive haemorrhage), inflammatory infiltration of the sympathetic trunk (Horner's syndrome), descending necrotic inflammation of the mediastinum, epidural abscess, necrotic fascitis, aspiration pneumonia, septicaemia, septicopyemia, and metastatic abscesses [26].

A clinical image of the patient with retropharyngeal abscess is often ambiguous, and in the early stages of the disease poorly symptomatic. The main symptoms are non-specific ailments such as: sore throat, flu-like symptoms, disorders while swallowing, and pain in the cervix limiting its movement [5, 27]. Respiratory disorders are not always present. In the examination of the patient, sialosis and enlargement of cervical lymph nodes appear, and according to Pollard and El-Beheiry, bulging of the rear wall of the throat occurs in only 37% of cases [28]. Grisaru-Soen et al. found that the most common symptoms of retropharyngeal abscess are fever (70%) and neck pain (62%) [12]. In view of the non-specificity of disease symptoms, making a diagnosis of retropharyngeal abscess can be difficult, and can delay the initiation of proper treatment [14, 15, 23, 24, 27]. In each case of suspected abscess in this anatomical area it is appropriate to include a broad-spectrum antibiotic therapy and nonsteroidal antiphlogistic drugs [12, 29]. For non-specific retropharyngeal abscesses, Harkani et al. propose the combination of intravenous antibiotic therapy: amoxicillin + aminoglycosides + imidazole [25]. They also believe that the necessary diagnostic examination in adults to confirm the presence of an abscess in the retropharyngeal space is CT of the neck with contrast, while in children magnetic resonance imaging (MRI) of the neck is recommended. In the literature the position prevails that the examination of choice in patients with a suspected retropharyngeal abscess should be CT with contrast [12, 29, 30]. This examination, in addition to visualizing the inflammatory process in the retropharyngeal space, also allows the assessment of the condition and the position of cervical vessels [31]. Some authors, in addition to broad-spectrum antibiotic therapy, postulate surgical treatment – drainage of the abscess [27, 32, 33]. Surgical methods involve two approaches: intraoral and transcervical [4, 5, 13, 15, 22, 25].

In patients with small abscesses, puncture and antibiotic therapy is used [21, 25, 34]. Stability of glycaemia level is important in patients with diabetes suffering from retropharyngeal abscess [19, 35]. In patients treated with immunosuppressive, immunomodulatory or cytostatic drugs, who suffer from retropharyngeal abscess, it is recommended to discontinue these drugs for the time the abscess is being treated [23].

Patients with a retropharyngeal abscess require a proper diagnosis and rapid conservative treatment (antibiotic therapy),

and in justified cases also surgical treatment [22, 25, 27, 32, 33]. McClay et al. claim that children with infections of the deep spaces of the neck can be treated successfully only conservatively (antibiotic therapy) [36]. Similar observations were reported by Page et al., who believe that small retropharyngeal abscesses in children can be treated conservatively [5]. The literature does not indicate clearly which cases of abscesses in adults should be treated surgically and which only conservatively. Quite consistently, numerous authors postulate the implementation of surgical treatment of retropharyngeal abscess in diabetic patients [19, 35]. Surgical treatment methods, which involve the puncture and drainage of the abscess with intraoral and transcervical access, are described [4, 5, 13, 15, 22, 25, 26, 32, 33]. Although there are advantages and disadvantages in both these methods, the therapeutic results are similar. Some authors believe that puncture and intraoral drainage should be used as a first-choice method, and transcervical access if there is no improvement, or recurrence of the abscess [4, 37]. Some authors prefer less invasive methods. Yeow et al. described 15 patients treated successfully using puncture performed under USG control and aspiration of abscess content, leaving the catheter in the cavity of the abscess [34]. These authors did not observe complications after this procedure.

The bacterial flora identified most often in retropharyngeal abscesses are aerobic bacteria (*beta-hemolytic Streptococcus* and *Staphylococcus aureus*), anaerobic bacteria (*Bacteroides* and *Veillonella*), and Gram-negative bacteria (*Haemophilus parainfluenzae* and *Bartonella henselae*) [25]. In the described case in cultures of material collected from retropharyngeal abscesses a Gram-positive bacterium was found – *Enterococcus faecalis*. This bacterium is part of the physiological flora of the digestive tract (including the oral cavity) and genitourinary system. This bacterium is often present in infected root canals [38]. According to Molander et al., *Enterococcus faecalis* constitutes the flora of infected root canals in up to 70% of teeth with infected pulp [39]. Pinheiro et al. assessed the sensitivity of this bacteria isolated from root canals to antibiotics [40]. Azithromycin and erythromycin proved to be the least effective, while vancomycin, penicillin, tetracycline and doxycycline proved to be the most effective. Similar studies were also conducted by Noda et al., who found the resistance of *Enterococcus faecalis* isolated from the root canal exudate of periapical lesions to cephalosporin [41]. They demonstrated that penicillin and ofloxacin are most effective in controlling infections with this bacterium. It should be pointed out that in none of the above tests was the usefulness of clindamycin in eliminating *Enterococcus faecalis* specified, because this bacterium shows natural resistance to this antibiotic.

Cultures of material taken from retropharyngeal abscesses prepared by Harkani et al. usually contained *Staphylococcus aureus* [25]. In empirical antibiotic therapy of retropharyngeal abscesses the same authors used amoxicillin with clavulanic acid, gentamicin and metronidazole for 14 days on average. They reported that the average time of hospital treatment in patients with retropharyngeal abscess was 9 days (6–15 days).

## CONCLUSIONS

The use of an author-devised rinsing drain in the reported case had the following advantages:

- it allowed for the spontaneous (passive) evacuation of suppurative content during the time when the drain was kept in the abscess cavity,
- it enabled effective active lavage of the abscess cavity with rinsing solutions in different directions because of the presence of numerous multilateral perforations in the part of the drain placed in the abscess cavity,
- it allowed for an effective discharge of lavage fluid created during the surgical rinsing without applying excessive pressure in the retropharyngeal space,
- in cases of a need of revision surgery (lack of therapeutic effect and/or confirmed presence of suppurative abscesses in the retropharyngeal space) the rinsing drain could serve as a guide alongside which the residual abscesses could be easily reached,
- if there was a lack of therapeutic effect and/or confirmed presence of residual abscesses, drain repositioning could be attempted.

## REFERENCES

1. Harnsberger HR, Osborn AG, Macdonald A, Ross JS. Diagnostic and surgical imaging anatomy: brain, head & neck, spine. Amirsys; 2006. p. 126-257.
2. Gervasio A, Mujahed I, Biasio A, Alessi S. Ultrasound anatomy of the neck: The infrathyroid region. *J Ultrasound* 2010;13:85-9.
3. Wang B, Gao BL, Xu GP, Xiang C. Images of deep neck space infection and the clinical significance. *Acta Radiol* 2014;55:945-51.
4. Lander L, Lu S, Shah RK. Pediatric retropharyngeal abscesses: a national perspective. *Int J Pediatr Otorhinolaryngol* 2008;72:1837-43.
5. Page NC, Bauer EM, Lieu JE. Clinical features and treatment of retropharyngeal abscess in children. *Otolaryngol Head Neck Surg* 2008;138:300-6.
6. Costa NS, Salisbury SR, Donnelly LF. Retropharyngeal lymph nodes in children: a common imaging finding and potential source of misinterpretation. *AJR Am J Roentgenol* 2011;4:433-7.
7. Georget E, Gauthier A, Brugel L, Verlhac S, Remus N, Epaud R, et al. Acute cervical lymphadenitis and infections of the retropharyngeal and parapharyngeal spaces in children. *BMC Ear Nose Throat Disord* 2014;5:14-8.
8. Cmejrek RC, Cotichia JM, Arnold JE. Presentation, diagnosis, and management of deep-neck abscesses in infants. *Arch Otolaryngol Head Neck Surg* 2002;128:1361-4.
9. Phillipott CM, Selvadurai D, Banerjee AR. Paediatric retropharyngeal abscess. *J Laryngol Otol* 2004;118:919-26.
10. Jaworsky D, Reynolds S, Chow AW. Extracranial head and neck infections. *Crit Care Clin* 2013;29:443-63.
11. Shefelbine SE, Mancuso AA, Gajewski BJ, Ojiri H, Stringer S, Sedwick JD. Pediatric retropharyngeal lymphadenitis: differentiation from retropharyngeal abscess and treatment implications. *Otolaryngol Head Neck Surg* 2007;136:182-8.
12. Grisaru-Soen G, Komisar O, Aizenstein O, Soudack M, Schwartz D, Paret G. Retropharyngeal and parapharyngeal abscess in children – epidemiology, clinical features and treatment. *Int J Pediatr Otorhinolaryngol* 2010;74:1016-20.
13. Awasthi SK, Dutta A, Verghese BK. A case of post traumatic retropharyngeal abscess. *Indian J Otolaryngol Head Neck Surg* 2006;58(3):281-3. doi: 10.1007/BF03050842.
14. Hirshoren N, Gross M, Weinberger JM, Eliashar R. Retropharyngeal infected hematoma: a unique complication of nasogastric tube insertion. *J Trauma* 2009;67:891.
15. Vourexakis Z, Konu P. Retropharyngeal abscess complicating “innocent” foreign body ingestion. *BMJ Case Rep* 2014. doi: 10.1136/bcr-2014-204010.
16. Ziad T, Rochdi Y, Benhoummad O, Nouri H, Aderdour L, Raji A. Retropharyngeal abscess revealing a migrant foreign body complicated by mediastinitis: a case report. *Pan Afr Med J* 2014;19:125. doi: 10.11604/pamj.2014.19.125.5334.
17. Hugar BS, Chandra YP, Babu PR, Jayanth SH, Vinay J. Fatal case of retropharyngeal abscess associated with Pott's disease. *J Forensic Leg Med* 2013;20:567-9.
18. Alawad AA, Khalifa AF. A rare cause of retropharyngeal abscess: cervical Pott's disease. *Am J Trop Med Hyg* 2015;92:884.
19. Kilic D, Findikcioglu A, Ates U, Hekimoglu K, Hatipoglu A. Management of descending mediastinal infections with an unusual cause: a report of 3 cases. *Ann Thorac Cardiovasc Surg* 2010;16:198-202.
20. González-García R, Risco-Rojas R, Román-Romero L, Moreno-García C, López García C. Descending necrotizing mediastinitis following dental extraction. Radiological features and surgical treatment considerations. *J Craniomaxillofac Surg* 2011;39(5):335-9. doi: 10.1016/j.jcms.2010.10.001.
21. Sato K, Izumi T, Toshima M, Nagai T, Muroi K, Komastu N, et al. Retropharyngeal abscess due to methicillin-resistant *Staphylococcus aureus* in a case of acute myeloid leukemia. *Intern Med* 2005;44:346-9.
22. Kakarala K, Durand ML, Emerick KS. Retropharyngeal abscess in the setting of immune modulation for rheumatoid arthritis. *Laryngoscope* 2010;120 Suppl 4:131.
23. Rajanna DM, Manickavasagam J, Jewes L, Capper R. Retropharyngeal abscess from an unusual organism – *Kingella denitrificans* – in a patient on low-dose methotrexate. *Ear Nose Throat J* 2011;90:15-7.
24. Pak MW, Chan KL, van Hasselt CA. Retropharyngeal abscess. A rare presentation of nasopharyngeal carcinoma. *J Laryngol Otol* 1999;113:70-2.
25. Harkani A, Hassani R, Ziad T, Aderdour L, Nouri H, Rochdi Y, et al. Retropharyngeal abscess in adults: five case reports and review of the literature. *Scientific World Journal* 2011;11:1623-9.
26. Herzon FS, Martin AD. Medical and surgical treatment of peritonsillar, retropharyngeal, and parapharyngeal abscesses. *Curr Infect Dis Rep* 2006;8(3):196-202.
27. Sharma SB, Hong P. Ingestion and pharyngeal trauma causing secondary retropharyngeal abscess in five adult patients. *Case Rep Emerg Med* 2012;2012:943090. doi: 10.1155/2012/943090.
28. Pollard BA, El-Beheiry H. Pott's disease with unstable cervical spine, retropharyngeal cold abscess and progressive airway obstruction. *Can J Anaesth* 1999;46:772-5.
29. Jabłońska-Jesionowska M, Zawadzka-Głós L. Trudności diagnostyczne w rozpoznawaniu ropni głębokich szyi: przestrzeni przygardłowej i zagardłowej u dzieci. *Nowa Pediatr* 2014;4:115-8.
30. Benmansour N, Benali A, Piorrier AL, Cherkaoui A, Oudidi A, Elalami MN. Retropharyngeal abscess in adults. *Rev Laryngol Otol Rhinol (Bord)* 2012;133:137-9.
31. Hedge A, Mohan S, Lim WE. Infections of the deep neck spaces. *Singapore Med J* 2012;53:305-11.
32. Ozbek C, Dagli S, Tuna EE, Ciftci O, Ozdem C. Giant retropharyngeal abscess in an adult complication of acute tonsillitis: case report. *Ear Nose Throat J* 2009;88:20-2.
33. Schuler PJ, Cohen M, Greve J, Plettenberg C, Chereath J, Bas M, et al. Surgical management of retropharyngeal abscesses. *Acta Otolaryngol* 2009;129:1274-9.
34. Yeow KM, Hao SP, Liao CT. US-guided percutaneous catheter drainage of a deep retropharyngeal abscess. *J Vasc Interv Radiol* 1999;10:1365-9.
35. Chang GH, Tsai YT, Chang CC, Yeh RA. Infected Tornwaldt's cyst leading to life-threatening retropharyngeal abscess in a diabetic patient. *Otolaryngol Head Neck Surg* 2015;153:695-6.
36. McClay JE, Murray AD, Booth T. Intravenous antibiotic therapy for deep neck abscesses defined by computed tomography. *Arch Otolaryngol Head Neck Surg* 2003;129:1207-12.
37. Nwaorgu OG, Onakoya PA, Fasunla JA, Ibekwe TS. Retropharyngeal abscess: a clinical experience at the University College Hospital Ibadan. *Niger J Med* 2005;14:415-8.
38. Pawlicka H, Pietrzak P. *Enterococcus faecalis* – its role in endodontic treatment and elimination methods from the infected root canals – review of literature. *Dent Med Probl* 2007;44:390-5.

39. Molander A, Lundquist P, Papapanou PN, Dahlén G, Reit C. A protocol for polymerase chain reaction detection of *Enterococcus faecalis* and *Enterococcus faecium* from the root canal. *Int Endod J* 2002;35:1-6.
40. Pinheiro ET, Gomes BP, Drucker DB, Zaia AA, Ferraz CC, Souza-Filho FJ. Antimicrobial susceptibility of *Enterococcus faecalis* isolated from canals of root filled teeth with periapical lesions. *Int Endod J* 2004;37:756-63.
41. Noda M, Komatsu H, Inoue S, Sano H. Antibiotic susceptibility of bacteria detected from the root canal exudate of persistent apical periodontitis. *J Endod* 2000;26:221-4.