

An analysis of the effect of the technique of the repair and postoperative rehabilitation protocol on the treatment outcomes of flexor tendon injuries: a review

Andrzej Żyluk^A✉, Bernard Piotuch^B

Pomeranian Medical University in Szczecin, Department of General and Hand Surgery, Unii Lubelskiej 1, 71-252 Szczecin, Poland

^A ORCID: 0000-0002-8299-4525; ^B ORCID: 0000-0001-9337-8077

✉ azyluk@hotmail.com

ABSTRACT

This study covers updated information on the methods of the repair of flexor tendon injuries, postoperative rehabilitation protocols and their effect on treatment outcomes. Contemporary techniques of flexor tendon repair are based on combinations of various types of core sutures and circumferential epitendon sutures. Literature shows a tendency of replacing earlier 2-strand core tendon sutures with novel multistrand core sutures, however the results of meta-analyses do not confirm any definitive

superiority over traditional techniques. Likewise, literature does not provide conclusive evidence that early active postoperative mobilization results in better outcomes than active-passive and controlled passive mobilization techniques. The choice of the method of flexor tendon repair and postoperative rehabilitation protocol depends only in part on scientific evidence, but more on individual or institutional preference of the surgeon.

Keywords: flexor tendon; repair; postoperative rehabilitation; functional outcomes.

INTRODUCTION

The tendon is an anatomical structure transferring force from a contracting muscle into flexion or extension of a joint. Tendons are composed of very durable collagen fibres with subtle vascularity. Within the upper extremities, tendons begin as a smooth natural prolongation of the muscles at ¼ distal length of the forearm. The distal ends of the tendons connect to the bones of the phalanges to provide extension and flexion of the fingers, as the basis of the gripping function. The anatomy of the flexor tendons is regular and straightforward. Each of the fingers and the thumb is equipped with 2 flexor tendons: superficial (other name – sublimis) and profundus; in the thumb they are named flexor pollicis longus and brevis. Both flexor tendons pass through the carpal tunnel to the metacarpus, then run between the lumbrical muscles to the ends of the fingers. On the metacarpus and at the proximal phalanx of the fingers, the superficial flexor tendon lays above the profundus. On the finger the positions change where the superficial tendon splits into 2 slips passing under the profundus, and then both parts insert to the bone of the middle phalanx. The profundus flexor tendon runs along the finger to the distal phalanx where it connects to the bone. In the finger, both flexor tendons are surrounded by thick fibrous sheath. The origin of this structure is located on the palm at the metacarpophalangeal joint. The fibrous flexor tendon sheath is an important structure, protecting the tendon near the bones of the phalanges during flexion of the fingers. Any great defect of the fibrous sheath results in bowstringing of the tendons during finger flexion, translating into impaired (reduced) finger motion.

Zones of the flexor tendons

For practical reasons, several zones along the flexor tendons have been distinguished. The 1st classification and distribution of 5 flexor tendon zones was proposed by Kleinert and Verdan in 1983 (Fig. 1). There were several reasons justifying this concept:

- path of the tendons along anatomical structures, i.e. phalanges, metacarpus or carpal tunnel;
- other anatomical structures surrounding the tendons, i.e. lumbrical muscles or fibrous flexor tendon sheath.

The practical aspect of this classification was associated with the methods of repair of tendon injuries in particular zones, and most of all with prognoses of a return to normal function after a repair.

Repair (suturing) of injured tendons developed in the beginning of 20th century, but results from the first operations were poor: either the suture of the tendon failed or movement of the finger with the repaired tendon was very limited. At the beginning of 1970s, new effective techniques of tendon suturing were invented and used in practice, which allowed for significant improvement in the treatment outcomes. To date, these techniques have been modified and advanced, and the repair of flexor tendon injuries has been under continuous development. New materials, varieties of suture configurations and the number of strands (methods by Tsuge, Tang, Savage, Strickland and Adelaide), as well as novel post-operative rehabilitation protocols, offer surgeons the possibilities of effective tendon repair and the perspective of satisfactory treatment outcomes [1, 2, 3].

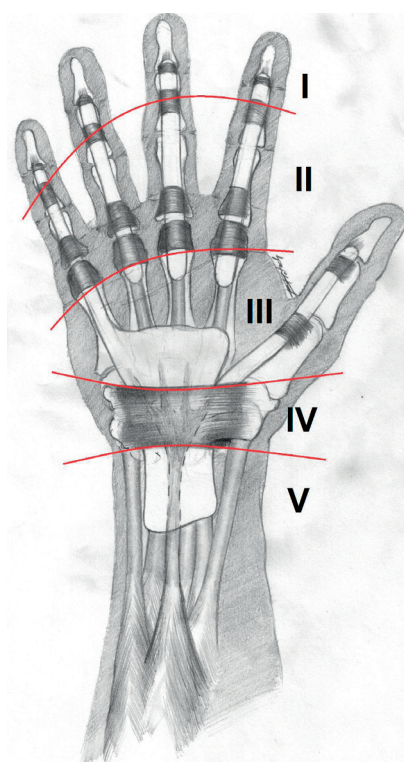


FIGURE 1. Five zones of the flexor tendons according to the Kleinert-Verdan classification

FACTORS INFLUENCING THE HEALING OF REPAIRED TENDONS AND TREATMENT OUTCOMES

Suturing of the flexor tendon is the most complicated and technically demanding technique of soft tissue repair compared other surgical disciplines, resulting from the necessity of meeting several difficult conditions [4, 5]:

- it should be strong enough to allow motion of the tendon soon after the repair,
- tight contact between stumps of the divided tendon, without any gap, but also with no over-compression,
- preservation of the subtle tendon vascular (nutrition) system to promote healing,
- smooth contact area (surface) between the repaired stumps, allowing for unrestricted motion of the tendon inside the tight fibrous sheath.

All these conditions have a significant effect on the healing of the repaired tendon stumps and on the final range of movement of the affected finger, and arise from the necessity of finger movement almost immediately following the repair to prevent adhesions forming between the tendon and the fibrous tendon sheath, or between the tendons (superficial and profundus) themselves. Motion itself promotes healing and assists in better functional treatment outcomes. This particularly concerns where the tendons move inside the tight fibrous sheath, in the 2nd Kleinert-Verdan zone, where movement should ideally be smooth.

Meeting these conditions is difficult, and pushes researchers to conduct experimental and clinical studies to create optimal techniques of tendon suturing, satisfying the following components in obtaining satisfactory treatment outcomes [4, 5]:

- configuration (construct) of the core (internal) suture,
- number of strands of the core suture (2 vs. 4 vs. 6),
- method of insertion of the suture in the tendon between succeeding bites (grasping vs. locking),
- configuration of epitenon sutures (simple circumferential vs. cruciate),
- suturing material (monofilament vs. braided thread).

Over and above these technical factors, several other variables, mostly related to the trauma, influence treatment outcomes [6, 7]:

- type of injury (clean-cut, laceration, crush),
- zone of the injury (2nd zone is most demanding, with relatively poorer outcomes),
- loss of the tendon body (deteriorates treatment outcomes),
- isolated injury of just the profundus flexor tendon vs. division of both tendons (prognosis is better in the former situation),
- number of repaired fingers (better outcomes in single digit injury than in repair of multiply tendons in several digits),
- age of the patient (poorer outcomes in children <10 years of age and in older patients >60 years old).

TECHNICAL COMPONENTS OF TENDON SUTURING: THE NUMBER OF STRANDS AND THEIR CONFIGURATION

Contemporary methods of flexor tendon repair are based on combinations of various core sutures and circumferential epitenon sutures. The epitenon suture, although relatively superficially placed and aimed at smoothing the repair site, significantly strengthens the repair and reduces the rate of failures after tendon suturing – Figure 2 [4, 6]. The core sutures are the most controversial issue and a matter of numerous studies: they differ in the number of strands, the configuration inside the tendon stumps, the methods of passing the suture inside the tendon and in other details [7, 8]. Still, by the end of 1900s, the 2-strand Bunnel and Kessler sutures (Fig. 3 a, b) were the most popular and commonly used; being characterised by limited mechanical resistance, permitting a specific postoperative rehabilitation protocol called “Kleinert dynamic traction”. However, when newer rehabilitation methods, i.e. early active motion protocol were introduced, failures of 2-strand repairs were observed more frequently [9, 10]. Modern multistrand techniques (Adelaide or Savage) are characterized by greater endurance against snapping *in vitro* and *in vivo*, enabling more intensive rehabilitation protocols after flexor tendon repair with these sutures (Fig. 3 c, d and Fig. 4 a, b).

In vitro experimental studies have revealed greater mechanical endurance and resistance to snapping in multistrand tendon sutures compared to 2-strand techniques [3, 11, 12, 13, 14, 15]. Forces transferred by a healthy flexor tendon during passive and active finger flexion without any resistance range from 0.2–27 N, and 2–48 N with 5 N resistance [16]. Resistance to snapping

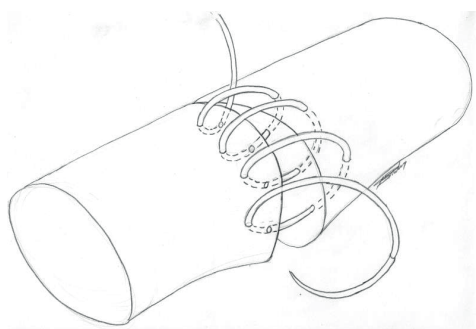


FIGURE 2. Simple continuous epitendon suture

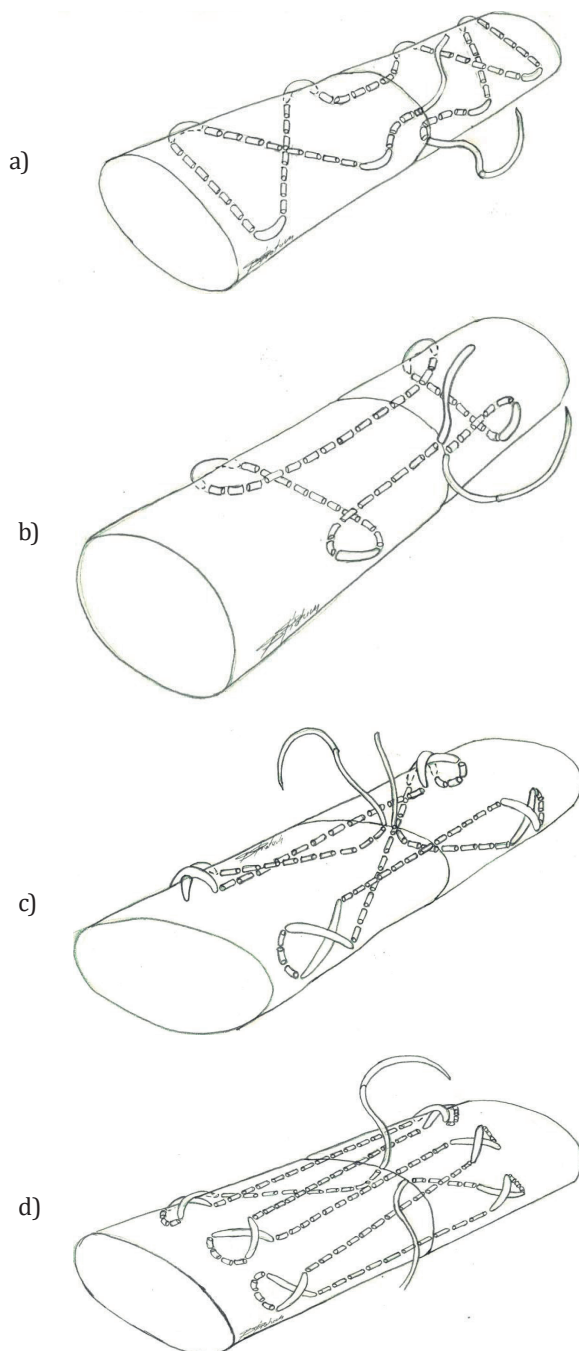
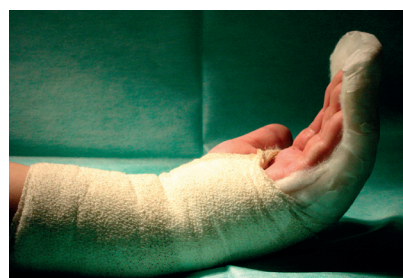

FIGURE 3. Schematic drawings of various core sutures: a) 2-strand Bunnell technique; b) 2-strand Kessler technique; c) 4-strand Adelaide suture; d) 6-strand Savage suture

a)



b)

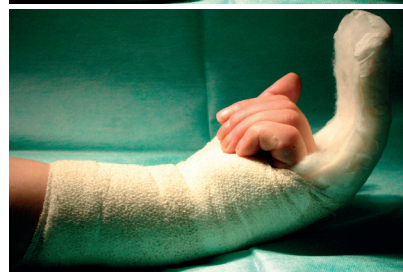

FIGURE 4. Early active motion protocol of postoperative rehabilitation: a) active extension; b) active flexion

a 2-strand tendon repair is about 20–28 N, a 4-strand is about 43–46 N and a 6-strand is above 60 N [12, 13]. The resistance is also dependent on the method of anchoring the suture: “locking” repairs show greater resistance than grasping sutures [17]. It is obvious that a stronger repair technique significantly reduces the risk of failure during rehabilitation or involuntary use the involved finger, i.e. at grasping an object. These results pushed forward the popularity of multistrand suturing techniques and their wider use in clinical practice over the older 2-strand repairs. In the 21st century this popularity is quite obvious [17].

There are known drawbacks in multistrand techniques. Multiple sutures, even buried deep inside the tendon body, increase the surface friction characteristics of the repaired tendon, in particular against the fibrous tendon sheath. This fact and swelling (always occurring after injury) results in a significant increase in resistance forces generated during passive and active finger movements [10, 18]. These considerations have affected the 8-strand suture, despite its very good endurance, and which is not used in clinical practice due to the very poor gliding characteristics [10]. The results of experimental studies on human cadaveric tendons revealed that full flexion of the finger with the flexor tendon repaired by a 6-strand suture, requires twice the effort than does a repair with a 2-strand suture [19]. The big increase in resistance is induced by the greater volume of the multistrand repair, causing more friction of the repair through the fibrous tendon sheath. This may further translate into restriction of movement of the finger during rehabilitation and – finally – to poorer outcomes of the treatment. One of the techniques of decreasing of the friction of the repair against the tendon sheath consists of a 2–3 cm incision above the repair site, called venting pulley [7]. This manoeuvre enables unrestricted motion of the repair and full finger flexion and extension. It should be performed with caution, because a too long incision of the sheath (pulley) may result in bowstringing of the tendon, which significantly compromises finger movement.

LITERATURE REVIEW ON OUTCOMES OF FLEXOR TENDON REPAIRS

While literature offers many publications comparing different methods of flexor tendon repair, most of them are based on the results of experimental studies without verification in clinical practice. There are also numerous clinical studies available, but only a few meet the criteria of scientific evidence (prospective, randomized and controlled trials). In this paragraph we present a review of several meta-analyses concerning outcomes of tendon repairs, with regard to the type of the core suture (2-strand vs. multistrand) and protocol of postoperative rehabilitation.

Hardwicke et al. presented the results of a meta-analysis of literature on the outcomes of flexor tendon surgery, comparing the results between multistrand and 2-strand repairs. The authors analysed data from 48 published articles, of which 5 were based on the results of prospective randomized trials, and 41 on the results of non-randomized or retrospective. The flexor tendon repairs were performed across a total of 2585 digits in 1878 patients, with 15 examples from a 2-strand repair, and 33 examples from a 4–6-strand repair. Of the total number of 2585 operated digits, 60% reported just the profundus flexor tendon and 38% reported both flexors. The flexor pollicis longus tendon was repaired in 2% of patients. The rate of failure (break) of the repair and functional results in at least one of the following classifications: Strickland–Glogovac, Buck–Gramcko or American Society for Surgery of the Hand were considered primary outcome measures. Results:

- the mean rate of failure was 3.9% and was unrelated to the type of core suture (2-strand or multistrand),
- the type of core suture had no significant effect on the functional outcome (in any of the classifications),
- a direct comparison of treatment outcomes in zone II did not show any significant difference between methods of the repair (2-strand vs. multistrand),

- the type of 2-strand suture – modified Kessler (634 digits) vs. other technique (110 digits) made no significant difference.

The only perceptible difference reported by the authors was a statistically significant more frequent use of a venting pulley over the site of the repair following multistrand sutures (50%) compared to 2-strand sutures (22%) [20].

Hoffmann et al. compared the results of flexor tendon repairs using the 4-strand Lim/Tsai technique (51 digits in 46 patients) vs. the classical 2-strand Kessler method (26 digits in 25 patients) which was performed with 4/0 non-absorbable thread and was locked to the tendon body. The multistrand group received 5 weeks of combined active-passive post-operative rehabilitation protocol with protection in a thermoplastic splint. The 2-strand group received controlled passive movements and Kleinert active-passive traction. At a follow-up (mean 3 months), 78% of patients in the 4-strand repair group received excellent and very good results in the Strickland–Glogovac classification, compared to 43% of patients in the 2-strand Kessler repair group, with only 1 (2%) and 3 (14%) failures, respectively. These differences were statistically significant, favouring the 4-strand Lin/Tsai technique [21]. This study is included in the meta-analysis and is presented as an example of the methodology used in the investigations on flexor tendon repair outcomes.

Giesen and Calcagni compared multiple reported outcomes of flexor tendon repairs in relation to the type of core suture, epitenon suture and rehabilitation protocol (Tab. 1). These results show that early active motion rehabilitation improves the functional outcomes of the treatment, comparing to active-passive Kleinert traction, but it is associated with an increased rate of repair failures. It is, however, not a 100% rule, as in one of the trials 7% breaking of the repair were noted following Kleinert traction method and 5% failures following early active mobilization (EAM). The results of this analysis also show that type of the core suture (2-strand vs. multistrand) had no significant effect on the rate of repair failures [22].

TABLE 1. A comparison of outcomes of flexor tendon repairs in relation to the type of core suture, epitenon suture and rehabilitation protocol [22]

Article	Number of fingers	Type of core suture	Rehabilitation protocol	Percent of failures	Percent of excellent and very good results
Früh et al.	138	4-strand + locked, circular epitenon	Kleinert	7%	53%
Quadlbauer et al.	115	2-strand + locked, circular epitenon	Kleinert	1%	90%
Farzad et al.	64	2-strand + circular epitenon	Kleinert and “place and hold”	0%	60%
Savvidou and Tsai	51	6-strand + circular epitenon	“place and hold” EAM from 3rd week	2%	81%
Total	380			3.2%	70%
Das et al.	52	2-strand + locked, circular epitenon	EAM	6%	84%
Al-Quattan	28	10-strand	EAM	0%	89%
Moriya et al.	97	6-strand + circular epitenon	EAM	5%	83%
Früh et al.	21	4-strand + locked, circular epitenon	EAM	5%	65%
Total	198			4.5%	83%

Kleinert – Kleinert dynamic traction (active extension – passive flexion); EAM – early active mobilization

Starr et al. compared 34 published outcomes of flexor tendon repairs with respect to the postoperative rehabilitation protocol: EAM vs. Kleinert dynamic traction combined with controlled passive movements. The data from 34 papers comprised 1564 patients with flexor tendon repairs, performed on a total of 2752 digits. Early active mobilization was used as the postoperative protocol in 25 studies, with 5% experiencing failures of the repair and 6% limited finger motion. Kleinert dynamic traction combined with controlled passive movements was utilised in 9 studies, with 4% experiencing failures of the repair and 9% limited finger motion. These differences, although minimal, were statistically significant. Conclusions from this analysis are consistent with previously presented works. The authors emphasize that constant development of the techniques of flexor tendon repair maintains the reduction in the risk of failures following EAM protocol [23].

Gibson et al. presented the results of a survey aimed at investigating trends in the current management of zone II flexor tendon repairs in the United States. Members of the American Society for Surgery of the Hand were mailed a questionnaire about their preferences in the treatment of flexor tendon lacerations. Four hundred and ten questionnaires were returned and from this number, 295 surgeons (72%) repaired injured flexor tendons with 4- or 6-strand core sutures, and 115 (28%) used a 2-strand core repair. All responders completed the repair with a running circular epitendon suture. With regard to sewing material, 90% of the surgeons used braided threads 3/0 or 4/0, and 10% preferred monofilament threads. A tendency appeared with respect to the age of the surgeons: older surgeons used 2-strand sutures, whereas younger surgeons preferred multistrand repairs. A similar tendency appeared in relation to the use of postoperative protocols: older surgeons indicated dynamic Kleinert traction more frequently, while younger surgeons indicated EAM protocol [24]. The results of that study show that the choice of technique used for flexor tendon repairs is only to some extent related to evidence-based medicine, and more frequently to the individual or institutional habits of the surgeons.

The results of this review show that treatment of flexor tendon lacerations remains a difficult clinical problem (a challenge), and outcomes following the repair are still far from perfection. The use of modern multistrand techniques is attracting increasing popularity and frequently replaces older 2-strand techniques, however the results of the meta-analyses fail to show a definitive favour of these techniques over traditional ones. The same concerns the use of postoperative rehabilitation protocols.

REFERENCES

1. Tsuge K, Ikuta I, Matsuishi Y. Repair of flexor tendons by intratendinous tendon suture. *J Hand Surg Am* 1977;2(6):436-40.
2. Savage R. In vitro studies of a new method of flexor tendon repair. *J Hand Surg Br* 1985;10(2):135-41.
3. Angeles JG, Heminger H, Mass DP. Comparative biomechanical performances of 4-strand core suture repairs for zone II flexor tendon lacerations. *J Hand Surg Am* 2002;27:508-17.
4. Khor WS, Langer MF, Wong R, Zhou R, Peck F, Wong JK. Improving outcomes in tendon repair: a critical look at the evidence for flexor tendon repair and rehabilitation. *Plast Reconstr Surg* 2016;138(6):1045e-58e.
5. Mehling IM, Arsalan-Werner A, Sauerbier M. Evidence-based flexor tendon repair. *Clin Plast Surg* 2014;41(3):513-23.
6. Dy CJ, Hernandez-Soria A, Ma Y, Roberts TR, Daluiski A. Complications after flexor tendon repair: a systematic review and meta-analysis. *J Hand Surg Am* 2012;37(3):e543-51.
7. Elliot D. Primary flexor tendon repair – operative repair, pulley management and rehabilitation. *J Hand Surg Br* 2002;27(6):507-13.
8. Strickland JW. Development of flexor tendon surgery: twenty-five years of progress. *J Hand Surg Am* 2002;25(2):215-35.
9. Elliot D, Moiemens NS, Flemming AS, Harris SB, Foster J. The rupture rate of acute flexor tendon repairs mobilized by the controlled active motion regimen. *J Hand Surg Br* 1994;19(5):607-12.
10. Amadio PC. Friction of the gliding surface. Implications for tendon surgery and rehabilitation. *J Hand Ther* 2005;18(2):112-9.
11. Savage R, Risitano G. Flexor tendon repair using a „six-strand” method of repair and early active immobilisation. *J Hand Surg* 1989;14:396-9.
12. Xie RG, Zhang S, Tang JB, Chen F. Biomechanical studies of 3 different six-strand flexor tendon repair techniques. *J Hand Surg Am* 2002;27:621-7.
13. Cao Y, Tang B. Biomechanical evaluation of a four-strand modification of the Tang method of tendon repair. *J Hand Surg Br* 2005;30:374-8.
14. Lawrence TM, Davis TR. A biomechanical analysis of suture materials and their influence on four-strand flexor tendon repair. *J Hand Surg Am* 2005;30(4):836-41.
15. Gill RS, Lim BH, Shatford RA, Toth E, Voor MJ, Tsai TM. A comparative analysis of the six-strand double-loop flexor tendon repair and three other techniques: a human cadaveric study. *J Hand Surg Am* 1999;24(6):1315-22.
16. Powell ES, Trail IA. Forces transmitted along human flexor tendons during passive and active movements of the fingers. *J Hand Surg Br* 2004;29(4):386-9.
17. Xie RG, Xue HG, Gu HJ, Tan J, Tang JB. Effects of locking area on strength of 2- and 4-strand locking tendon repairs. *J Hand Surg Am* 2005;30(3):455-60.
18. Tang JB, Gu YT, Rice K, Chen F, Pan CZ. Evaluation of four methods of flexor tendon repair for postoperative active mobilization. *Plast Reconstr Surg* 2001;107(3):742-9.
19. Aoki M, Manske PR, Pruitt DL, Larson BJ. Work of flexion after tendon repair with various suture methods. A human cadaveric study. *J Hand Surg Br* 1995;20(3):310-3.
20. Hardwicke JT, Tan JJ, Foster MA, Titley OG. A Systematic review of 2-strand vs multistrand core suture techniques and functional outcome after digital flexor tendon repair. *J Hand Surg Am* 2014;39:686-95.
21. Hoffmann GL, Buchler U, Vogelin E. Clinical results of flexor tendon repair in zone II using a six-strand double-loop technique, compared with a two-strand technique. *J Hand Surg* 2008;33E:418-23.
22. Giesen T, Calcagni M. Systematic review of flexor tendon rehabilitation protocols after acute flexor tendon repair in zone II. Budapest: FEESH Instructional book; 2017.
23. Starr HM, Snoddy M, Hammond KE, Seiler JG 3rd. Flexor tendon rehabilitation protocols: a systematic review. *J Hand Surg Am* 2013;38(9):1712-7. doi: 10.1016/j.jhsa.2013.06.025.
24. Gibson PD, Sobol GL, Ahmed IH. Zone II flexor tendon repairs in the United States: trends in current management. *J Hand Surg Am* 2017;42(2):e99-e108.